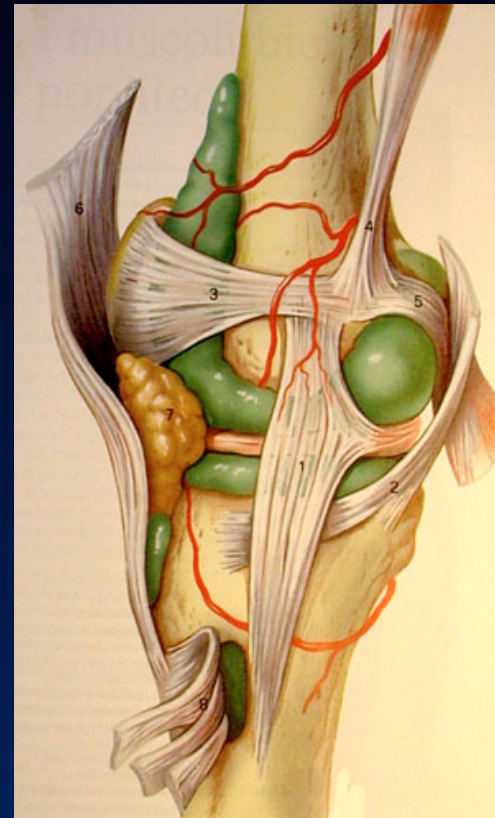
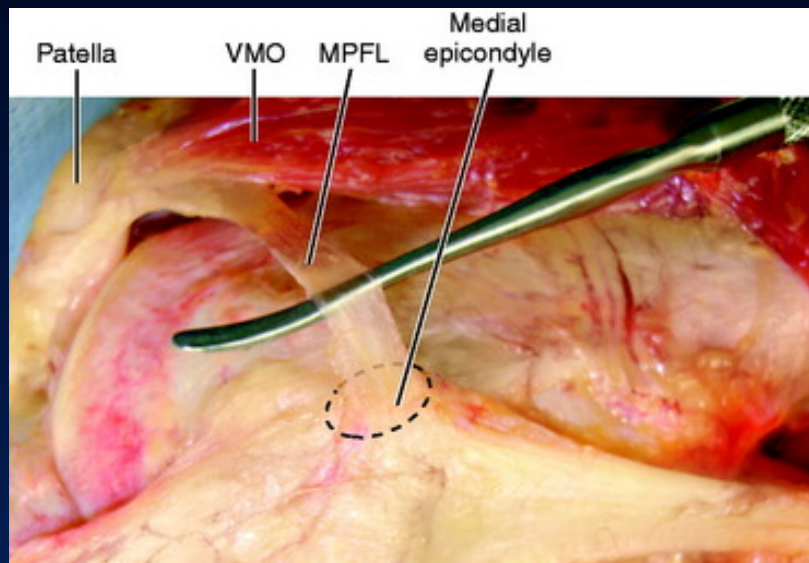


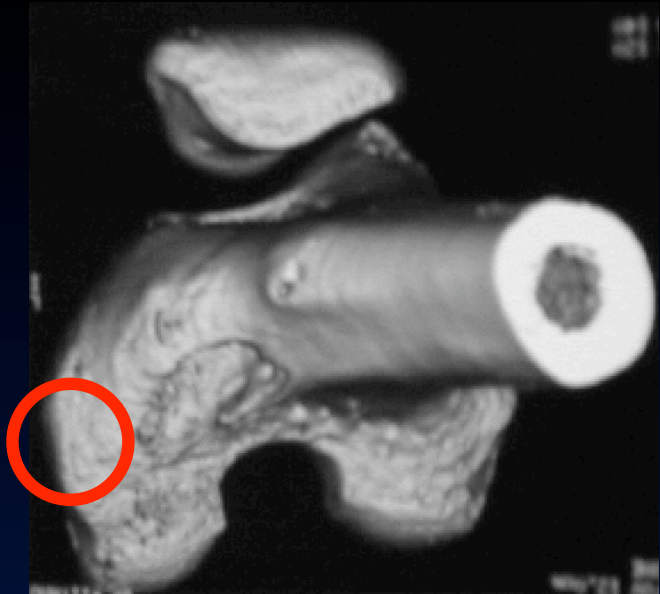
MPFL Femoral Spot



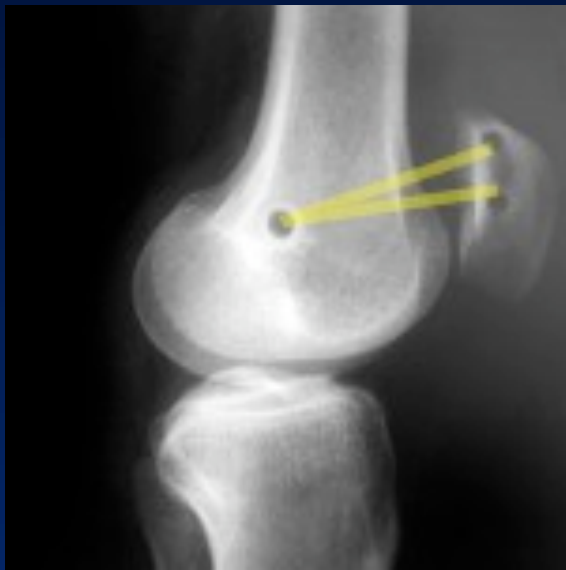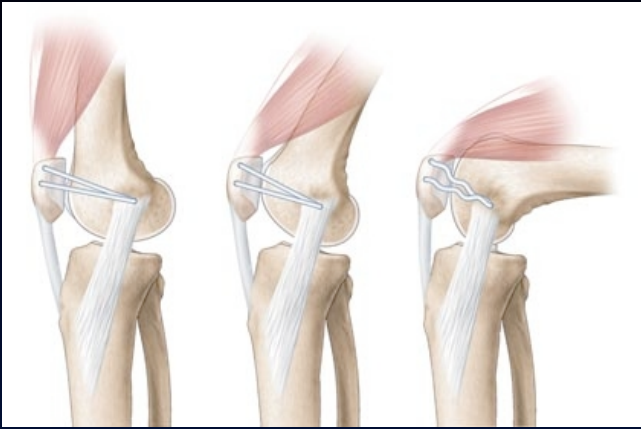
François Kelberine, Jean Philippe Vivona

Aix en Provence

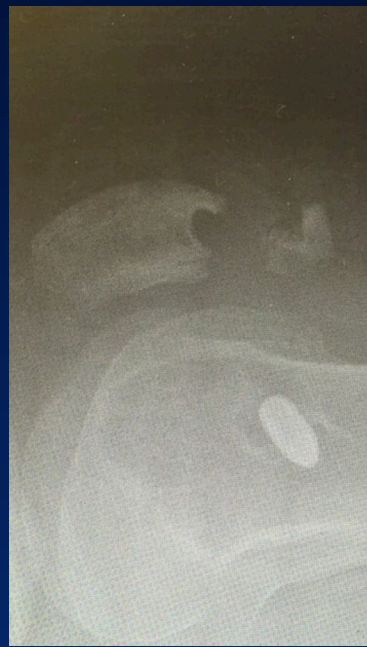



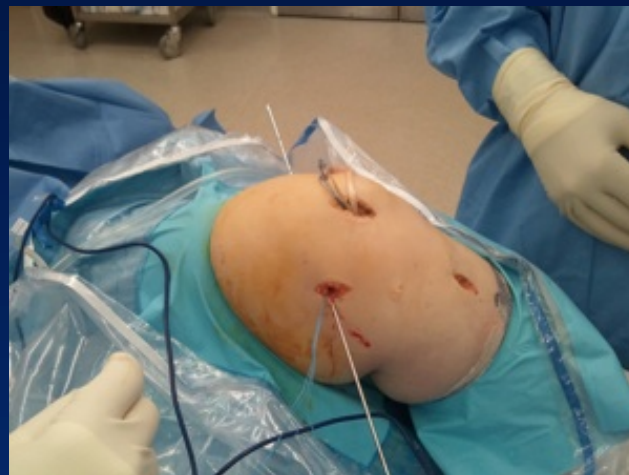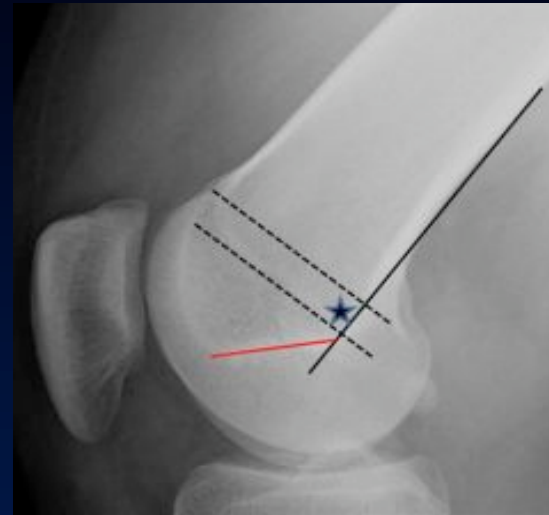
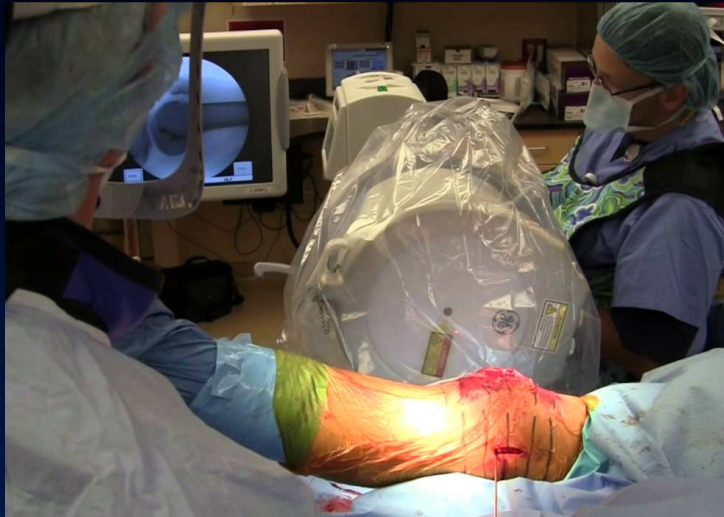Non isometric
Slack > 40°
Rope on an Easel



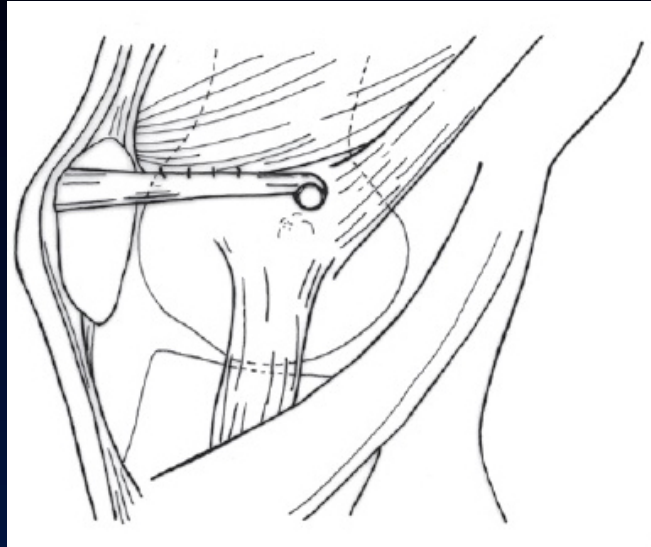
??



X-ray recommended

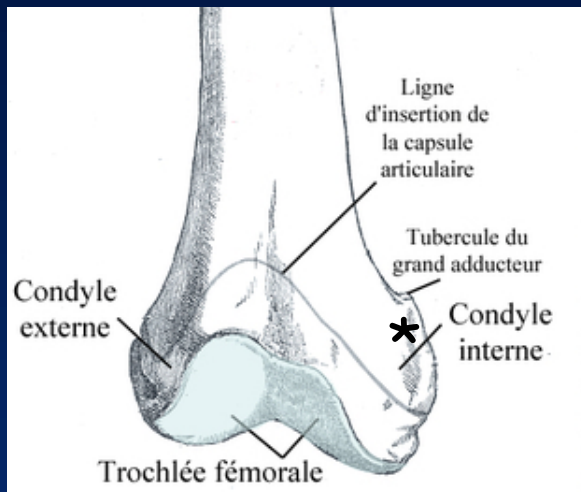
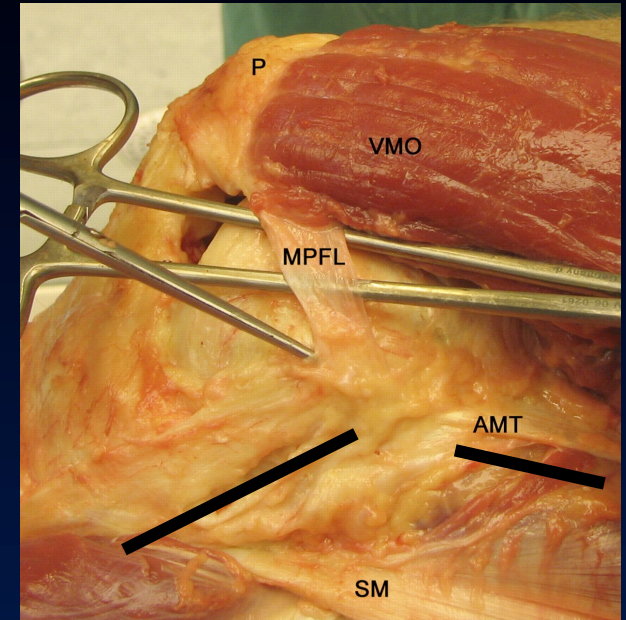


Femoral insertion site

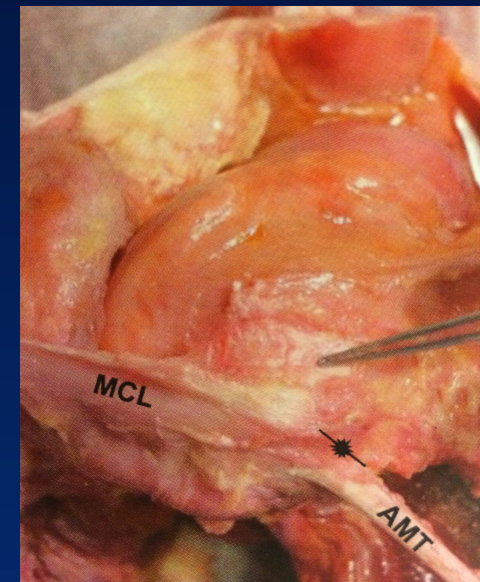


Post sup / Sup MCL

Ant Inf / AMT

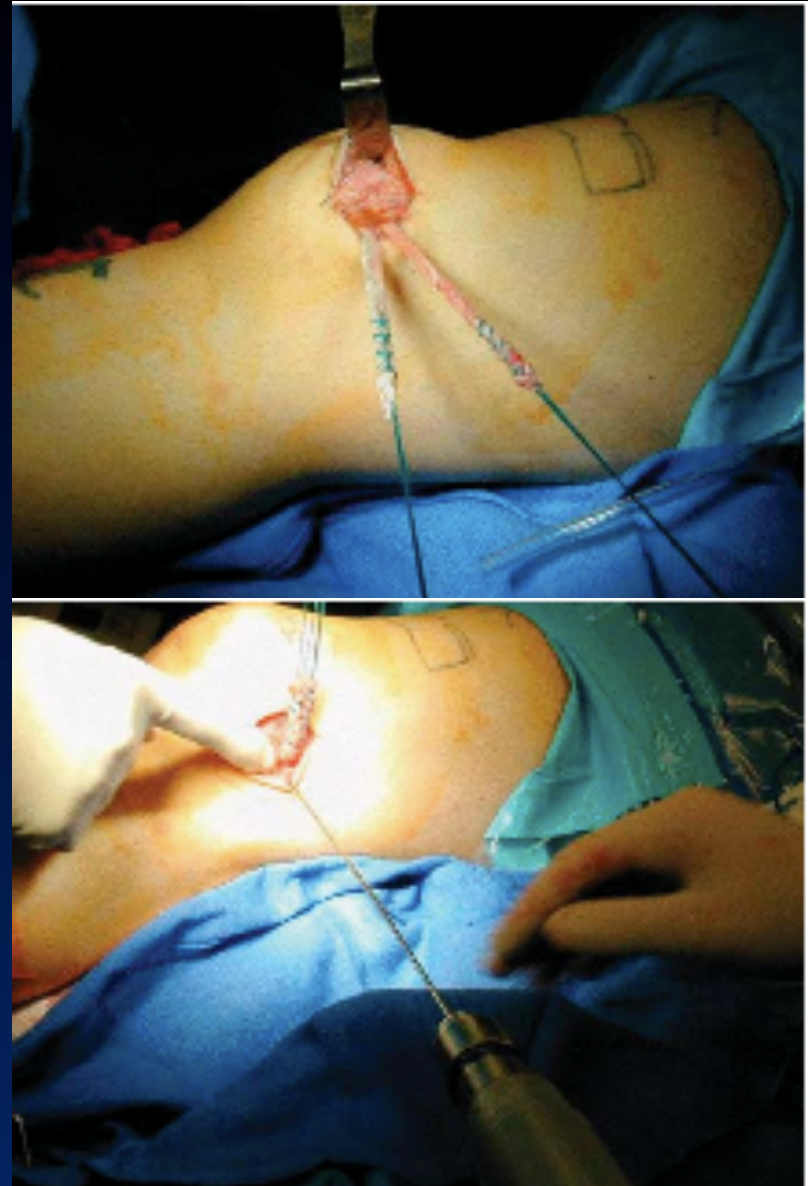

PALPABLE GROOVE



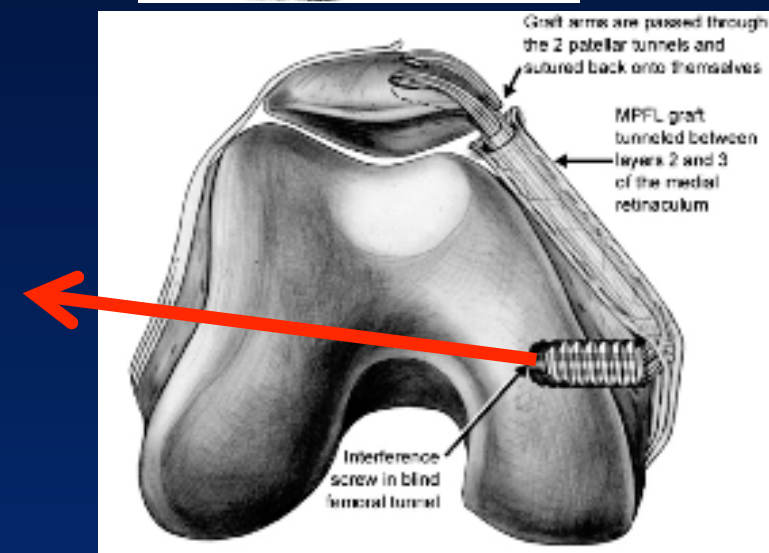
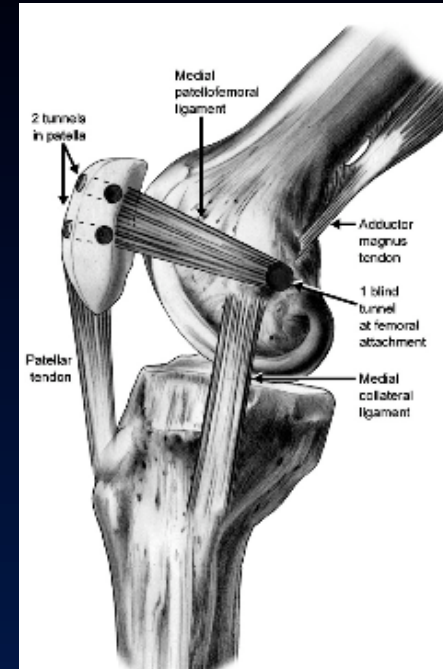
Approach

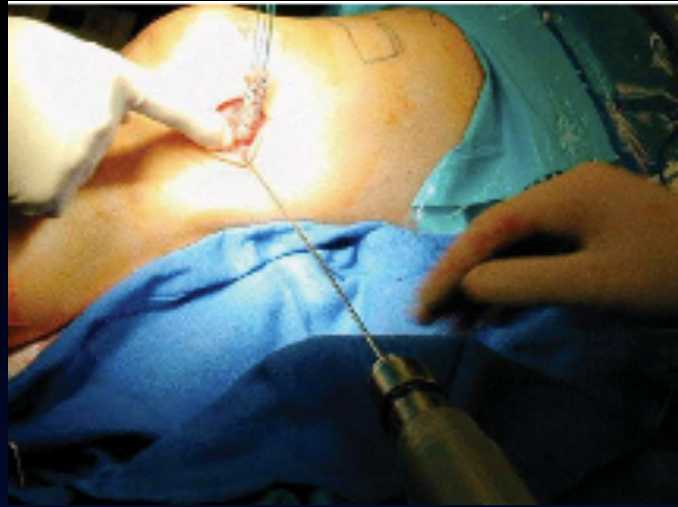- One vertical incision
Mobile window
- EA reconstruction under
the remnants
- Large enough for palpation
 - Medial epicondyle & MCL
 - MAT & its tubercle
 - Groove



Track of the femoral tunnel

- 7 mm Ø blind socket
- Direction of transcondylar pin
 - Over the notch
 - Slightly anteriorly oriented





- Friendly user
- Reproducible
- Think anatomy rather than trick

